



MINNESOTA

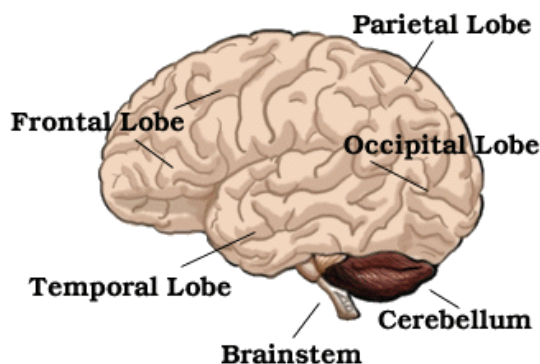
Brain Injury Alliance

Engaging Communities. Improving Lives.

Information copyrighted by authors listed and may not be photocopied for mass distribution.

About Brain Injury: A Guide to Brain Anatomy

Information from <http://www.waiting.com>, © 1997-2002, Becca, Ltd.



BRAIN ANATOMY DEFINITIONS

Brainstem: The lower extension of the brain where it connects to the spinal cord. Neurological functions located in the brainstem include those necessary for survival (breathing, digestion, heart rate, blood pressure) and for arousal (being awake and alert). Most of the cranial nerves come from the brainstem. The brainstem is the pathway for all fiber tracts passing up and down from peripheral nerves and spinal cord to the highest parts of the brain.

Cerebellum: The portion of the brain (located at the back) which helps coordinate movement (balance and muscle coordination). Damage may result in ataxia, which is a problem of muscle coordination. Ataxia can interfere with a person's ability to walk, talk, eat, and to perform other self-care tasks.

Frontal Lobe: Front part of the brain; involved in planning, organizing, problem solving, selective attention, personality and a variety of "higher cognitive functions" including behavior and emotions.

The anterior (front) portion of the frontal lobe is called the prefrontal cortex. It is very important for the "higher cognitive functions" and the determination of the personality.

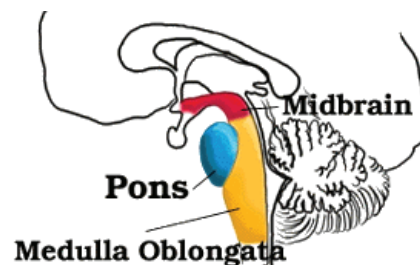
The posterior (back) of the frontal lobe consists of the premotor and motor areas. Nerve cells that produce movement are located in the motor areas. The premotor areas serve to modify movements.

The frontal lobe is divided from the parietal lobe by the central sulcus.

Occipital Lobe: Region in the back of the brain which processes visual information. Not only is the occipital lobe mainly responsible for visual reception, it also contains association areas that help in the visual recognition of shapes and colors. Damage to this lobe can cause visual deficits.

Parietal Lobe: One of the two parietal lobes of the brain located behind the frontal lobe at the top of the brain.

Parietal Lobe, Right - Damage to this area can cause visuo-spatial deficits (e.g., the patient may have difficulty finding their way around new, or even familiar, places).





MINNESOTA

Brain Injury Alliance

Engaging Communities. Improving Lives.

Information copyrighted by authors listed and may not be photocopied for mass distribution.

Parietal Lobe, Left - Damage to this area may disrupt a person's ability to understand spoken and/or written language.

The parietal lobes contain the primary sensory cortex which controls sensation (touch, pressure). Behind the primary sensory cortex is a large association area that controls fine sensation (judgment of texture, weight, size, and shape).

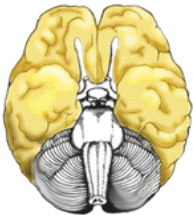
Temporal Lobe: There are two temporal lobes, one on each side of the brain located at about the level of the ears. These lobes allow a person to tell one smell from another and one sound from another. They also help in sorting new information and are believed to be responsible for short-term memory.

Right Lobe - Mainly involved in visual memory (i.e., memory for pictures and faces).

Left Lobe - Mainly involved in verbal memory (i.e., memory for words and names).

About Brain Injury:

The Areas of the Brain, Their Function, & Associated Signs & Symptoms

Brain Structure	Function	Associated Signs and Symptoms
<p>Cerebral Cortex</p> 	<p>The outermost layer of the cerebral hemisphere which is composed of gray matter. Cortices are asymmetrical. Both hemispheres are able to analyze sensory data, perform memory functions, learn new information, form thoughts and make decisions.</p>	
<p>Left Hemisphere</p>	<p>Sequential Analysis: systematic, logical interpretation of information. Interpretation and production of symbolic information: language, mathematics, abstraction and reasoning. Memory stored in a language format.</p>	

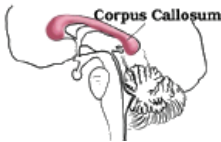
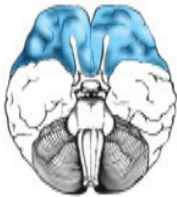
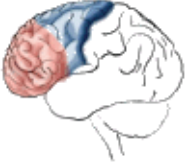



MINNESOTA

Brain Injury Alliance

Information copyrighted by authors listed and may not be photocopied for mass distribution.

Engaging Communities. Improving Lives.

	<p>Holistic Functioning: processing multi-sensory input simultaneously to provide “holistic” picture of one’s environment. Visual spatial skills. Holistic functions such as dancing and gymnastics are coordinated by the right hemisphere. Memory is stored in auditory, visual and spatial modalities.</p>	
<p>Corpus Callosum</p>  <p>Frontal Lobe</p>   <p>Parietal Lobe</p> 	<p>Connects right and left hemisphere to allow for communication between the hemispheres. Forms roof of the lateral and third ventricles.</p> <p>Cognition and memory. Prefrontal area: The ability to concentrate and attend, elaboration of thought. The “Gatekeeper”; (judgment, inhibition). Personality and emotional traits. Movement: Motor Cortex (Brodmann’s): voluntary motor activity. Premotor Cortex: storage of motor patterns and voluntary activities. Language: motor speech.</p> <p>Processing of sensory input, sensory discrimination.</p> <p>Body orientation.</p> <p>Primary/ secondary somatic area.</p>	<p>Damage to the Corpus Callosum may result in “Split Brain” syndrome.</p> <ul style="list-style-type: none"> • Impairment of recent memory, inattentiveness, inability to concentrate, behavior disorders, difficulty in learning new information. Lack of inhibition (inappropriate social and/or sexual behavior). Emotional lability. “Flat” affect. • Contralateral plegia, paresis. • Expressive/motor aphasia. <ul style="list-style-type: none"> • Inability to discriminate between sensory stimuli. • Inability to locate and recognize parts of the body (Neglect). • Severe Injury: Inability to recognize self. • Disorientation of environment space. • Inability to write.



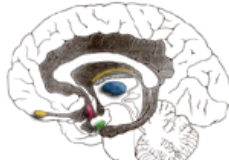
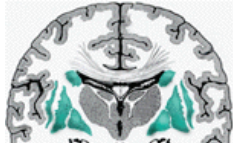
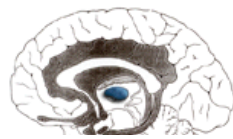


MINNESOTA

Brain Injury Alliance





Information copyrighted by authors listed and may not be photocopied for mass distribution.

Engaging Communities. Improving Lives.

<p>Occipital Lobe</p> 	<p>Primary visual reception area. Primary visual association area: Allows for visual interpretation.</p>	<ul style="list-style-type: none"> • Primary Visual Cortex: loss of vision opposite field. • Visual Association Cortex: loss of ability to recognize object seen in opposite field of vision, “flash of light”, “stars”.
<p>Temporal Lobe</p> 	<p>Auditory receptive area and association areas.</p> <p>Expressed behavior.</p> <p>Language: Receptive speech.</p> <p>Memory: Information retrieval.</p>	<ul style="list-style-type: none"> • Hearing deficits. • Agitation, irritability, childish behavior. • Receptive/ sensory aphasia.
<p>Limbic System</p> 	<p>Olfactory pathways:</p> <p>Amygdala and their different pathways.</p> <p>Hippocampi and their different pathways.</p> <p>Limbic lobes: Sex, rage, fear, and emotions. Integration of recent memory, biological rhythms.</p> <p>Hypothalamus.</p>	<ul style="list-style-type: none"> • Loss of sense of smell. • Agitation, loss of control of emotion. Loss of recent memory.
<p>Basal Ganglia</p> 	<p>Subcortical gray matter nuclei. Processing link between thalamus and motor cortex. Initiation and direction of voluntary movement. Balance (inhibitory), Postural reflexes.</p> <p>Part of extrapyramidal system: regulation of automatic movement.</p>	<ul style="list-style-type: none"> • Movement disorders: chorea, tremors at rest and with initiation of movement, abnormal increase in muscle tone, difficulty initiating movement. • Parkinson's.
<p>Thalamus</p> 	<p>Processing center of the cerebral cortex. Coordinates and regulates all functional activity of the cortex via the integration of the afferent input to the cortex (except olfaction).</p> <p>Contributes to affectual expression.</p>	<ul style="list-style-type: none"> • Altered level of consciousness. • Loss of perception. • Thalamic syndrome - spontaneous pain opposite side of body.



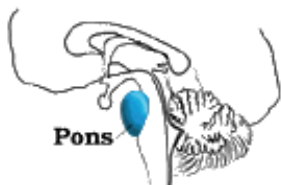Engaging Communities. Improving Lives.

<p>Hypothalamus</p> 	<p>Integration center of Autonomic Nervous System (ANS): Regulation of body temperature and endocrine function.</p> <p>Anterior Hypothalamus: parasympathetic activity (maintenance function).</p> <p>Posterior Hypothalamus: sympathetic activity (“Fight” or “Flight”, stress response).</p> <p>Behavioral patterns: Physical expression of behavior. Appetat: Feeding center. Pleasure center.</p>	<ul style="list-style-type: none"> • Hormonal imbalances. • Malignant hypothermia. • Inability to control temperature. • Diabetes Insipidus (DI). • Inappropriate ADH (SIADH). • Diencephalic dysfunction: “neurogenic storms”.
<p>Internal Capsule</p> 	<p>Motor tracts.</p>	<p>Contralateral plegia (Paralysis of the opposite side of the body).</p>
<p>Reticular Activating System (RAS)</p>	<p>Responsible for arousal from sleep, wakefulness, attention.</p>	<p>Altered level of consciousness.</p>
<p>Cerebellum</p> 	<p>Coordination and control of voluntary movement.</p>	<ul style="list-style-type: none"> • Tremors. • Nystagmus (Involuntary movement of the eye). • Ataxia, lack of coordination.
<p>Brain Stem:</p>		
	<p>Nerve pathway of cerebral hemispheres.</p> <p>Auditory and Visual reflex centers.</p> <p>Cranial Nerves:</p> <ul style="list-style-type: none"> • CN III - Oculomotor (Related to eye movement), [motor]. • CN IV - Trochlear (Superior oblique muscle of the eye which rotates the eye down and out), [motor]. 	<ul style="list-style-type: none"> • Weber’s: CN III palsy and ptosis (drooping) ipsilateral (same side of body). • Pupils: Size: Midposition to dilated. Reactivity: Sluggish to fixed. • LOC (Loss of consciousness): Varies • Movement: Abnormal extensor (muscle that extends a part). • Respiratory: Hyperventilating. • CN (Cranial Nerve) Deficits: CN III, CN IV.



Engaging Communities. Improving Lives.

Pons



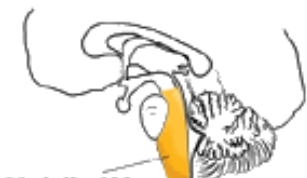Respiratory Center.

Cranial Nerves:

- CN V - Trigeminal (Skin of face, tongue, teeth; muscle of mastication), [motor and sensory].
- CN VI - Abducens (Lateral rectus muscle of eye which rotates eye outward), [motor].
- CN VII - Facial (Muscles of expression), [motor and sensory].
- CN VIII - Acoustic (Internal auditory passage), [sensory].

- Pupils: Size: Pinpoint
- LOC: Semi-coma
"Akinetic Mute"
"Locked In" Syndrome.
- Movement: Abnormal extensor. Withdrawal.
- Respiratory: Apneustic (Abnormal respiration marked by sustained inhalation).
- Hyperventilation.
- CN Deficits: CN VI, CN VII.

Medulla Oblongata



Crossing of motor tracts.

Cardiac Center.

Respiratory Center.

Vasomotor (nerves having muscular control of the blood vessel walls) Center Centers for cough, gag, swallow, and vomit.

Cranial Nerves:

- CN IX - Glossopharyngeal (Muscles and mucous membranes of pharynx, the constricted openings from the mouth and the oral pharynx and the posterior third of tongue.), [mixed].
- CN X - Vagus (Pharynx, larynx, heart, lungs, stomach), [mixed].
- CN XI - Accessory (Rotation of the head and shoulder), [motor].
- CN XII - Hypoglossal (Intrinsic muscles of the tongue), [motor].

- Movement: Ipsilateral (same side) plegia (paralysis).
- Pupils: Size: Dilated
Reactivity: Fixed.
- LOC: Comatose.
- Respiratory: Abnormal breathing patterns.
Ataxic.
Clustered.
Hiccups.
- CN Palsies (Inability to control movement):
- Absent Cough.
- Gag.

About Brain Injury: Intracranial Pressure

Does the brain always swell? How do you know if the brain is swelling? Doesn't the CT scan show swelling? Is it possible that the person's brain did not swell because of the use of the drug manitol (protocol treatment in all ICU's)? Is the chemical released if there is no swelling? If a person didn't need a shunt, can we assume there was no swelling?

Pretty much all tissues in the body swell when traumatized. They also require more oxygen to heal. The brain is unique in that it rests inside a bone case, so when it swells, it experiences more trauma.

The more damage the brain receives, the more it swells. This is caused by leakage from blood vessels. When the brain swells, because it is housed inside the skull, it has no room to expand. This leads to a rise in pressure within the brain. This rise in pressure rapidly equals the arterial pressure thereby affecting the blood flow to the brain. This diffuse pressure which decreases blood flow affects the ability of the cells within the brain to metabolize properly; the cells are unable to eliminate toxins which then accumulate.

This phenomenon leads to a spiral effect which is what kills brain injured people who don't get prompt attention. One of the big breakthroughs that lead to the survival rate we have now for brain injury today was learning to break this cycle. **We are still very much in the stage of learning to break this cycle. The most significant factor has been the use of monitoring devices to inform treatments to prevent further damage.**

The brain requires both oxygen and glucose. In response to the trauma, changes occur in the brain which require monitoring to prevent further damage. The brain's size frequently increases after a severe head injury. This is called brain swelling and occurs when there is an increase in the amount of blood to the brain.

Water may collect in the brain which is called Brain Edema. Both Brain swelling and Brain Edema result in excessive pressure in the brain called **Intracranial Pressure (ICP)**. Around-the-clock monitoring during this time is essential in order that ICP can be immediately treated. Treatment of brain swelling can be difficult. Very strong medications are administered. Medications which help to draw fluid back out of the brain and into blood vessels may be useful. Some medications help by decreasing the metabolic requirements of the brain. Other medications increase blood flow into the brain which can help diminish the spiral effect caused by brain swelling.

In some cases, removal of small amounts of fluids or from the brain or surgery may be beneficial. And in some cases, removal of damaged tissue may prevent further damage.